

Kerasoft® IC, a new silicone-hydrogel soft lens for correcting irregular astigmatism

Florence Malet¹, in collaboration with Anne Laveysse² and Pauline Grave²



Correcting irregular astigmatism is a task best suited for contact lenses, which offer the only means of effectively restoring visual acuity. The most appropriate lenses from a performance standpoint are rigid gas-permeable lenses: their multiple geometries make it possible to correct corneal asymmetries by means of the tear meniscus created under the lens. However, some patients cannot wear these lenses comfortably, despite testing designed to improve tolerance through the use of piggybacking lenses. These patients now have a highly attractive option in the form of a new silicone hydrogel soft lens. While thicker than a conventional soft lens, KeraSoft® IC doesn't rely solely on thickness since it utilizes unique aspheric optics to correct the vision. We evaluated the Kerasoft IC (Irregular Cornea) lens.

Technical characteristics of the lens

This lens has already been on the market in the United States and in several European countries for the past two years.

It is made of Etrofilcon A, which is 74% hydrophilic and has a Dk value of 60×10^{-11} , so provides an adequately oxygenated environment for the cornea. The lens is replaced every three months and is worn daily.

The lens's front surface is aspheric toric and prism-balanced. The front optic zone is wide: 8 mm. The internal surface of the lens has a spherical tricurve design with a posterior optic zone of 12.5 mm, for an overall diameter of 14.5 mm. The reference mark for lens stabilization is laser-engraved at 6:00 (Figure 1).

A wide range of curve radii is available, from 7.40 mm to 9.40 mm. It should be noted that there are various periphery options: a standard periphery offered as an initial option, a steepened periphery with four options (Steep, from 1 to 4) or a flattened periphery, also with four options (Flat, from 1 to 4). The diameter can vary from 14.00 mm to 15.50 mm.

The power range is extremely wide, since ametropia's range is from -30.00 to 30.00D. Cylindrical correction works for every axis (from 0 to 180°) and the range extends from -0.50D up to 15D!

Recommended fitting protocol

This protocol is based on slit-lamp examination of the corneal profile, displayed in a thin slit while the cornea is scanned. For especially irregular corneas, video topography is generally performed to identify the exact areas of corneal flattening and bulging.

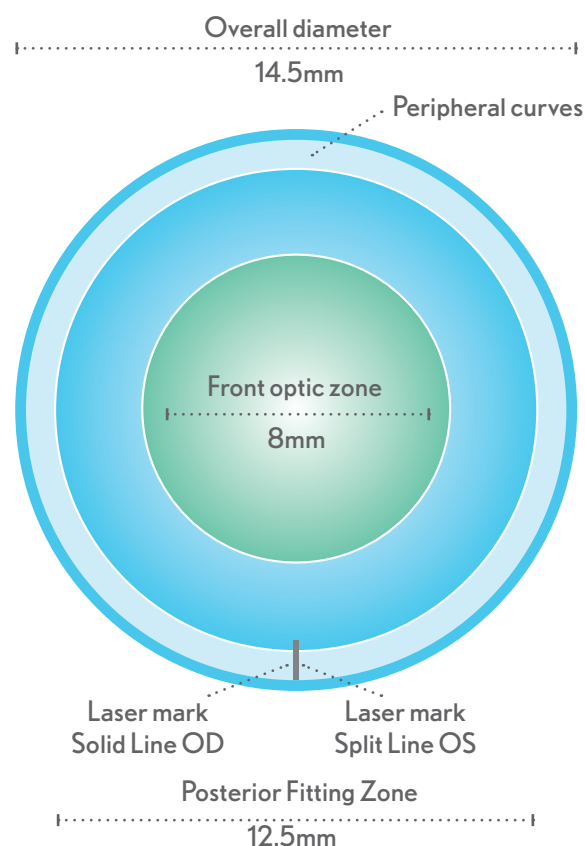


Figure 1: Geometry of the Kerasoft IC lens.

Five types of corneal profile can be identified and categorized as a basis for selecting an initial test lens (Figure 2):

- Type 1 profile (mild central ectasia): select a lens curve radius of about 8.40 to 8.80 mm, standard periphery;
- Type 2 profile: this shows a much more pronounced central ectasia that differs more markedly from the corneal periphery (more advanced central keratoconus). The ini-

Natural Ectasias	Topography	Normal	Mild	Moderate	Advanced	Type
Central Keratoconus Steep Periphery						Type 1: corneal profile curved at the center
Central Keratoconus Flat Periphery						Type 2: curved inferior central zone and curved overall periphery
Decentered/Low Cone						Type 3: cornea curved at the center, flat at the periphery
Pellucid Marginal Degeneration						Type 4: curved inferior periphery, very flat superior periphery
Post-Surgical			Post-surgical corneas are often flatter centrally and steeper peripherally but this is by no means a general rule.			Type 5: flat central cornea, periphery normal to curved

Figure 2: Protocol for fitting the Kerasoft IC lens (source: Ultravision).

tial recommendation for the radius will be about 7.80 to 8.00 mm, possibly with flattening of the peripheral portion of the lens;

- Type 3 profile: in these very low cone, decentered forms of keratoconus, the recommendation is to start with a radius of 8.40 to 8.60 mm;
- Type 4 profile: this shows cases of pellucid marginal degeneration. The most appropriate starting radius is flatter: about 8.60 to 8.80 mm. The periphery is always modified after the standard central radius has been se-

lected. The periphery may need to be made steeper on occasion (Steep from 1 to 4);

- Type 5 corneas are those in which the central corneal radius is flat (after either refractive surgery or keratoplasty). The recommended test lens will have a curve radius of 8.60 mm; the periphery will often be made steeper.

The criteria for proper fitting via biomicroscopy differ somewhat from the criteria for a typical soft lens because of the center thickness of the lens, which is about 400 microns. The lens must still be centered, but the spontaneous

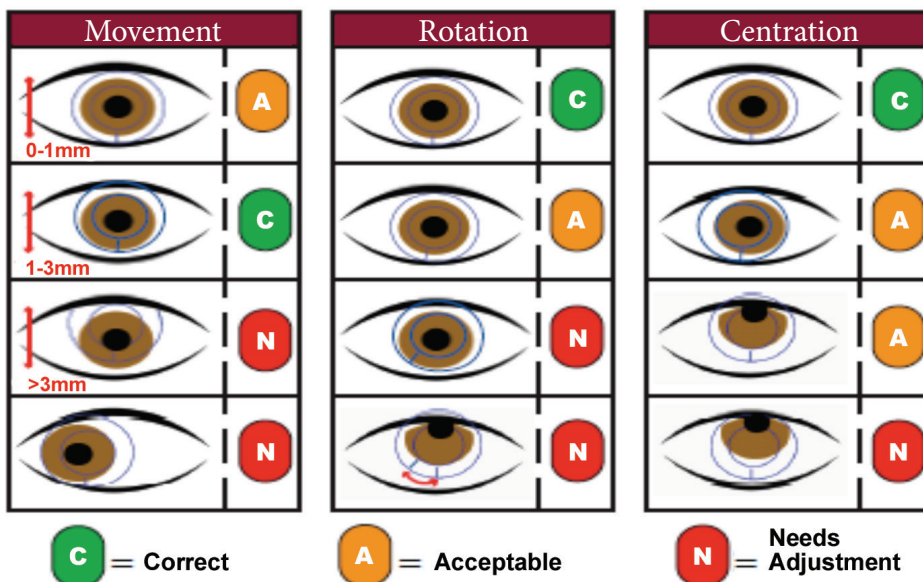


Figure 3: Verification of the lens fit under the slit-lamp.

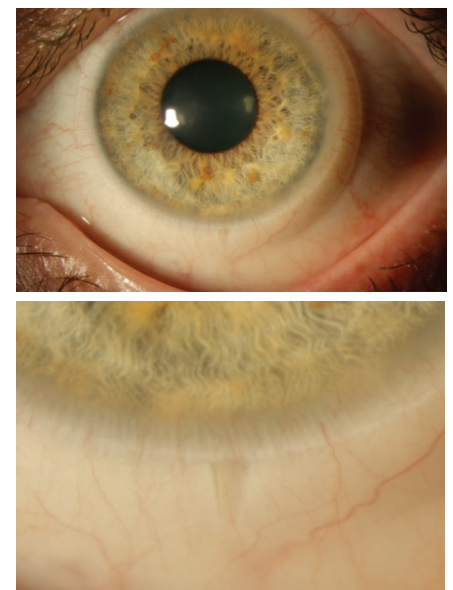

Figure 4: Position of the reference mark on the lens.

mobility required is more significant: a minimum of 1 mm and a maximum of 3 mm, which is substantially more than a typical silicone-hydrogel soft lens. This mobility will ensure stable, strong visual acuity (Figure 3). Spontaneous mobility will be evaluated after the lens has been worn for about twenty minutes. The position of the reference mark should be as close as possible to vertical, with minimal rotation (Figure 4).

In subjective terms, the wearer's level of comfort must not change after a few hours of wearing the lens; any irritation will indicate the lens is too steep. Visual acuity must remain stable after blinking, and this will be verified with any additional sphero-cylindrical correction provided by glasses with the lens in place.

Clinical evaluation of the Kerasoft IC

We fit 42 eyes in 28 patients having an average age of 35 (ages 22 to 65). These patients all reported unsatisfactory wearing comfort with rigid and/or piggyback lenses (worn less than 6 hours/day), or wore toric soft lenses because of complete intolerance of rigid lenses.

The fitting information was as follows:

26 cases of keratoconus: 18 eyes with unoperated keratoconus, six eyes in which intracorneal rings had been implanted and two in which penetrating keratoplasty had been performed;

- 6 cases of pellucid marginal degeneration;
- 8 post-Lasik ectasias, two of which had been treated with an intracorneal ring;
- 2 radial keratotomies.

During the fitting process, in addition to the usual keratometry and refractive measurements, we conducted elevation topographies using OrbscanII to assess whether the radius selected for the test lens could be refined. Statistical analyses comparing the radius ultimately used in the prescribed lens and the automated keratometry measurements did not reveal any correlation. A weak linear relationship was found between the measurement of the anterior best-fit sphere (BFS) and the curve radius of the lens ($r = 0.52$, $p = 0.02$), as follows:

$$\text{Radius_mm} = 0.30 \times \text{ant_BFS} + 6.13$$

Thus, recommended Ro for the lenses are as follows:

- For anterior BFS <6.00 mm, 8.00 mm
- For anterior BFS <7.60 mm, 8.40 mm
- For anterior BFS >7.60 mm, 8.60 mm

The visual acuity obtained with the Kerasoft IC provided an average gain of two lines compared with the equipment previously worn (Figure 5).

Measurement of higher-order aberrations, evaluated before and after fitting, showed a reduction in total aberrations (total Root Mean Square (RMS): 2.60 reduced to 2.06 RMS) and in comatic aberrations (which fell from 1.96 to 1.53).

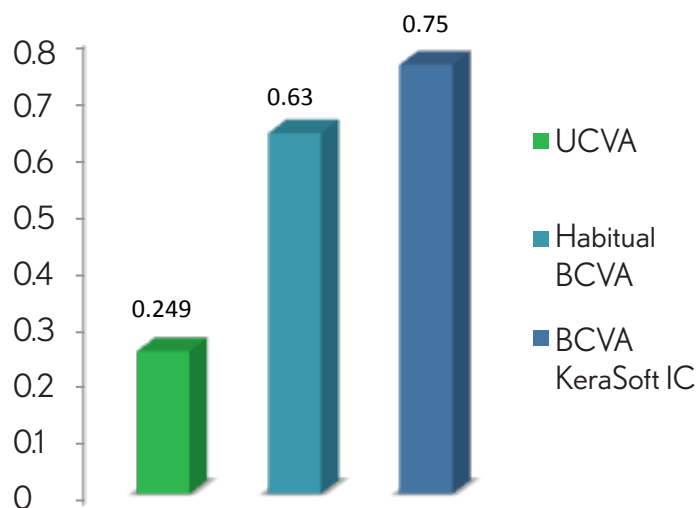


Figure 5. Visual acuity*, uncorrected, habitual, and with KeraSoft IC.

* 1.0 = 20/20 or 6/6

0.5 is equivalent to 20/40 or 6/12

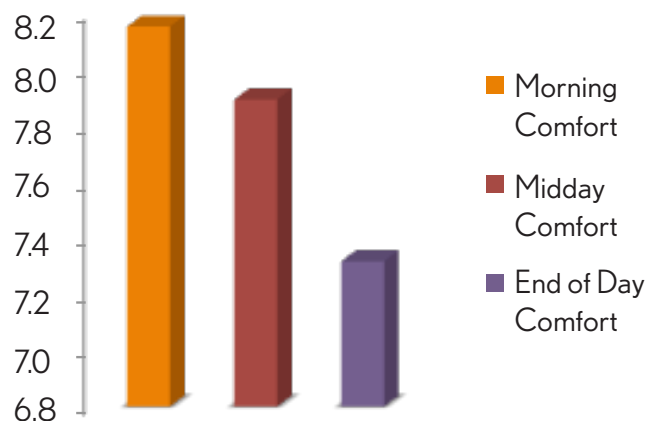


Figure 6. Average comfort after one month of wearing Kerasoft IC, at midday and at the end of the day (on a scale of 1 to 10).

Wearing comfort proved good with a moderate reduction at day's end.

Wearing comfort, after one month of wearing, proved good with a moderate reduction toward the end of the day: evaluated at between 7 and 8 on a 10-point analogical scale (0: discomfort; 10: excellent comfort) (Figure 6).

It should be noted that the optical benefits obtained were greatest in the surgical patients who were intolerant of RGPs and who wore toric soft lenses--in other words, in our selection, in the patients with intracorneal rings, either for keratoconus or for post-Lasik ectasia or after a corneal transplant. The broad range of parameters encompasses most cases of irregular corneas, although there are restrictions for highly advanced keratoconus (stage 3+ and 4).

This lens is a very attractive option for patients with irregular astigmatism who are difficult to fit with rigid lenses.